

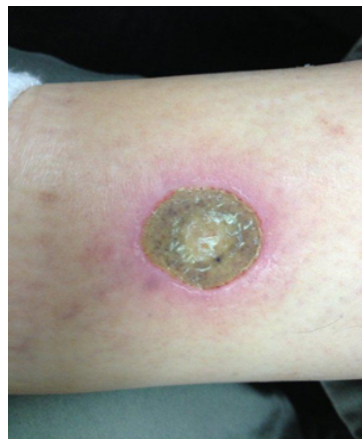# Case Study: Ulcerated Leg Wound

PCCA PracaSil™-Plus



**Summary:** A compounded medicine using PracaSil-Plus (**PCCA Formula #10843**) was applied topically in an open wound located on the leg of a diabetic patient, with outstanding healing results.

**Case Description:** A 61-year-old Caucasian male with type 2 diabetes, a sedentary lifestyle and an occupation that involves a seated position, presented with a 4 mm (approx.) diameter ulcer on his inner leg, from 8 to 10 mm above the right ankle (Figure 1). Treatment was initiated using a compounded medicine containing mupirocin 2% in PracaSil-Plus (Figure 2), which was applied topically to the ulcer three times daily. A second compounded medicine containing pentoxifylline 3% and nifedipine 3% in Lipoderm™ (Figure 3) was applied topically to the marginal area of the ulcer, also three times daily, in order to increase blood circulation. The patient was instructed to exercise every hour using an elastic band, also to improve blood flow to the ulcerated area. The wound was closed following 63 days of treatment (Figure 4).



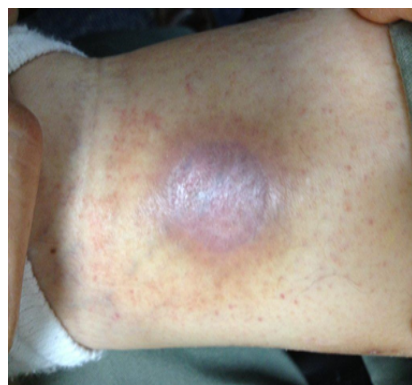
**Figure 1.** Ulcerated Leg Wound (before PracaSil-Plus formula)

Mupirocin USP	2 g
PCCA PracaSil™-Plus	98 g

**Figure 2.** PCCA Formula #10843

Pentoxifylline	3 g
Nifedipine	3 g
Lipoderm™	qs 100 g

**Figure 3.** PCCA Formula #10844



**Figure 4.** Ulcerated Leg Wound (after PracaSil-Plus formula)

**Patient Report:** *I developed an open wound on my right ankle. Everything that I was asked to do by my doctor didn't work and the wound was actually getting worse. A compounding pharmacist suggested two compounded medicines to be applied daily. In two months, my open wound was closed and the pain was gone. The treatment worked as promised.*

**Acknowledgements:** The patient agreed to anonymously share information and figures included in this case study. Figures 1 and 4 are courtesy of the patient. PCCA Science is grateful for the valuable information shared.

**Introduction:** PracaSil-Plus is a proprietary anhydrous silicone base designed to be applied topically in scar therapy treatment (PCCA, 2013a). Silicones have been widely used for their occlusion and hydration properties, which are essential in scar management (Widgerow *et al.*, 2000; Mustoe, 2008). PracaSil-Plus also contains Pracaxi oil, extracted from the oilseed plant *Pentaclethra macroloba*, which has several medicinal applications including skin regeneration and healing (Costa *et al.*, 2013). PracaSil-Plus may be used alone or as a base for the incorporation of active substances in scar therapy treatment (PCCA, 2013a).

**Research Studies:** The efficacy of PracaSil-Plus in scar therapy treatment was evaluated by visual and instrumental methods in an eight-week, randomized, double-blind, controlled pilot trial conducted on eleven adult Caucasian subject volunteers. PracaSil-Plus showed qualitative and quantitative improvements in the following scar attributes: scar length, scar color/pigment intensity, scar texture/ smoothness/roughness, and overall appearance in both old scars and new scars (PCCA, 2013b).

## References:

- Costa, M., Muniz, M., Negrao, C., Costa, C., Lamarao, M., Morais, L., Junior, J. and Costa, R. (2013) 'Characterization of *Pentaclethra macroloba* oil', *Journal of Thermal Analysis and Calorimetry*, 16 January 2013 [Online].
- Mustoe, T. (2008) 'Evolution of silicone therapy and mechanism of action in scar management', *Aesthetic Plastic Surgery*, 32 (1), p.82-92.
- PCCA (2013a) *PracaSil-Plus*. Available at: <http://www.pccarx.com/pcca-products/pcca-exclusives/bases/PracaSil-plus> (Accessed: 17 May 2013).
- PCCA (2013b) 'Efficacy of PracaSil-Plus in scar therapy treatment: a randomized, double-blind, controlled pilot trial', *Technical Report: 2TR0513*.
- Widgerow, A., Chait, L., Stals, R. and Stals, P. (2000) 'New innovations in scar management', *Aesthetic Plastic Surgery*, 24 (3), p.227-234.



Click the QR to see more PCCA studies and reports.